



Psychosocial Impact of Oral Cancer Diagnosis and Treatment: Role of Dental Professionals in Support and Rehabilitation- A Narrative Review

Lohit Arora^{1*}, Tanmay Popat², Devanshi Vala³, Ayush Shrotriya⁴,
Swagata Guha Roy⁵ and C Pradeep⁶

¹Consultant Head and Neck Oncology Department, Hindalco Hospital, Jharkhand, India

²Chief Consultant Prosthodontist, Carve Dental Wellness and Maxillofacial Prosthetic Rehab Centre, Kolkata, West Bengal, India

³Dental Consultant, Carve Dental Wellness and Maxillofacial Prosthetic Rehab Centre, Kolkata, West Bengal, India

⁴Stomatologist & Maxillofacial Radiologist, Dental Valley and Vrindavan Multispeciality Dental Care and Implant Centre Mathura, Uttar Pradesh, India

⁵Consultant Dental Surgeon, Vivekananda Hospital and Research Institute, Housestaff, Department of Dentistry, IPGME and R-SSKM Hospital, Kolkata, West Bengal, India

⁶Consultant Prosthodontist, Dentistrybytes Superspeciality Dental Care and Implant Centre, Nagapattinam, Tamil Nadu, India

*Corresponding Author: Lohit Arora, Consultant Head and Neck Oncology Department, Hindalco Hospital, Jharkhand, India.

DOI: 10.31080/ASDS.2024.08.1831

Received: April 05, 2024

Published: April 26, 2024

© All rights are reserved by Lohit Arora, et al.

Abstract

Oral cancer is a significant global health burden, characterized by a high mortality and morbidity rate. The prognosis for oral cancer is often poor, leading to low survival rates. Individuals diagnosed with oral cancer encounter numerous health-related complications. Additionally, individuals are at an increased risk of developing psychological challenges, underscoring the importance of addressing their mental health needs. Dentists play a multifaceted role in the fight against oral cancer, from early detection and prevention to ongoing management and supportive care. Their expertise and vigilance are indispensable in improving outcomes for patients affected by this disease. The current review delves into the psychosocial consequences experienced by patients following the diagnosis and treatment of oral cancer. It scrutinizes the profound impact on patients' mental and emotional well-being and explores the role of dentists in addressing these psychosocial challenges. Additionally, the review will outline techniques aimed at managing oral cancer postoperatively, emphasizing strategies to optimize patient recovery and quality of life.

Keywords: Oncology; Psycho-Oncology; Psychosocial Support OMFS; Artificial Intelligence; Reconstructive Surgery

Introduction

Oral cancer is prevalent worldwide with high incidence of mortality and morbidity. It is associated with poor prognosis and low survival rate. Patients are under great stress due to fear of death, treatment course and its side effects, social, family and economical constraints. The patients affected are more likely to develop psychological issues and thus, addressing psychological needs of such patients is crucial [1].

An estimated 3.9 million cases of cancer were reported in India in 2016. With 674,386 cases, Uttar Pradesh headed the country, followed by Maharashtra (364,997) and Bihar (359,228). Tamil Nadu had 222,748 cancer cases, Karnataka had 202,156, Andhra

Pradesh recorded 159,696, Telangana recorded 115,333, and Kerala recorded 115,511 cancer cases among the southern states [2].

This narrative review aims to delve into the multifaceted effects of oral cancer diagnosis and treatment on patients' lives, particularly focusing on the psychosocial aspects. Additionally, it discusses the crucial role that dental professionals play in providing support and rehabilitation throughout the entire journey.

Psychosocial impact of oral cancer

Psycho-oncology, a discipline concerned with the psychological reactions of cancer patients, as well as the psychological, social, and behavioral factors contributing to cancer (Holland, 2002), emerged

in the 1970s in response to various social (e.g., patient rights) and medical (e.g., improved treatment) factors [3]. In contemporary times, psychological services have become a standard and integrated component of cancer therapy.

Significance of emotional distress

Emotional distress in cancer patients is increasingly recognized for its significant impact on overall well-being and treatment outcomes. It has been described as the “sixth vital sign” in cancer patients, to be routinely assessed alongside pulse, respiration, blood pressure, temperature, and pain (Bultz and Holland, 2006) [3].

Patients undergoing radiation therapy (RT) or surgery combined with chemoradiation therapy can experience not only physical challenges but also functional impairments. These treatments can lead to severe side effects that further contribute to emotional distress and can exacerbate or lead to depression [4,5]. Changes in overall symptom severity, including swallowing difficulties, poor appetite, oral mucositis, pain, fatigue, and a dysmorphic appearance were all found to be significantly related to the severity of oral-cancer patients’ depression.

Depression has been found to be related to cancer patient symptom severity and level of physical functioning [6,7]. Lower survival rates and poorer outcomes have been demonstrated in cancer patients with depression as it adversely affects patient quality of life and may also interfere with treatments and rehabilitation [8,9].

Social and physical challenges

The increasing awareness of the psychological aspects of cancer in recent decades has been accompanied by consideration of its social aspects [10].

Facial disfigurement has been described as a state in which a person’s facial appearance has been medically severe and persistently damaged [11]. Despite advances in reconstructive surgery, oral cancer surgery can still lead to severe facial disfigurement depending on the location and stage of cancer. Facial disfigurement can negatively impact patients’ psychosocial well-being [12,13]. Appearance affects an individual’s body image and self-concept. Facial disfigurement makes contact with others difficult and embarrassing. The more concerned patients were about their facial deformities, the worse their body image, and the more likely they were to avoid social activities [13].

Patients with oral cancer experienced physical symptoms and side effects during and after treatment, with gradual remission over 3 to 12 months. Common symptoms in patients following oral cancer surgery include pain, dry mouth, sticky saliva, dental problems, and difficulty speaking, chewing, eating, and swallowing [14,15]. These symptoms can negatively impact a patient’s psychosocial adjustment.

Building upon the physical and psychosocial challenges faced by oral cancer patients, the role of social support becomes paramount in their care and recovery.

Social support is an essential resource for coping with stress and psychosocial adjustment. Past research has found that social support can help cancer patients manage psychological stress, reduce anxiety and depression, and improve their quality of life [16].

Post-treatment psychological challenges

Surgery for advanced oral cancer is often highly invasive. After their treatment, patients are left with impaired chewing, swallowing, and articulation functions, as well as aesthetic problems. It significantly affects their daily lives and inevitably reduces their quality of life. When patients are notified that they have cancer, face a life-threatening situation, and suffer a strong psychological Shock prior to treatment, they may develop a condition such as post-traumatic stress disorder (PTSD) [17].

Building on the challenges faced during and after treatment, psychological issues such as PTSD can further complicate a patient’s recovery and well-being.

PTSD is typically characterized by the following symptoms. The first is “intrusion” (re-experiencing symptoms), where memories of the experience flash back and recur as nightmares, causing somatic physiological reactions, such as palpitations and sweating. The second is “avoidance”, which are changes in mental activity, such as avoidance of events or situations that remind one of the experience, inability to recall parts of the experience, and decreased emotional response. The third is “hyperarousal”, which causes nervousness, excessive alertness, difficulty concentrating, irritability, and insomnia, as well as fear of even the slightest stimulus. The development of these symptoms prior to treatment may decrease motivation for and worsen psychological conditions during treatment, which may further deteriorate treatment outcome [18].

Effective communication in patient-centered care

Communication with the patient has been recognized as one of the most important skills used by practitioners to help approach difficult issues and focus on patients’ values and preferences. Professional–patient communication has several potential positive outcomes, including reduced patient anxiety, increased patient satisfaction, motivation and adherence to healthy behaviors, and better oral health outcomes [19-21].

Building on the importance of communication, specific protocols and models have been developed to guide practitioners in delivering bad news or discussing sensitive topics with patients.

There are protocols based on communicating bad news in the medical context and, in relation to the dentistry field, a recent review of the communication protocols in oral cancer patients showed available models such as SPIKES and ABCDE which recommend communication techniques considering patients' preferences [21,22]. In a personal-view study on telling the truth to patients with cancer, the author highlighted the following which could also be applicable in the context of OPMDs: "when the relationship between patients and their oncologists is recognized as an open-ended dynamic process of ascertainment and constant reassessment of a truth shared between them, it acquires a different strength and character. Truth-telling then becomes a bidirectional process aimed at constructing-rather than merely discovering-the truth and at helping people with cancer to make sense of having and living with their disease." [20].

Diagnosis of oral cancer

Oral squamous cell carcinoma (OSCC) is a well-known malignancy which accounts for more than 90% of all oral cancers. The overall 5-year survival rate in OSCC has not significantly increased in the last few years. The overall and disease-free survival rates are 56% and 58%, respectively. The most important task is to establish an early diagnosis at the first stages of the disease [23].

Currently, routine oral examination (visual and tactile inspection of accessible oral structures), together with tissue biopsy, remains the gold standard for diagnosing potentially malignant diseases (PMDs) and oral squamous cell carcinoma (OSCC) [24].

Noninvasive diagnostic adjuncts for the evaluation of potentially premalignant oral epithelial lesions include various methods and technologies aimed at aiding in the early detection and characterization of these lesions without the need for invasive procedures. Some commonly used noninvasive diagnostic adjuncts include.

- **Toluidine Blue Staining:** Toluidine blue is a vital dye that selectively stains areas of dysplasia or carcinoma in situ, aiding in the visualization of suspicious lesions during clinical examination [25].
- **Brush Biopsy (OralCDx®):** Brush biopsy is a non-invasive technique that collects surface cells from suspicious oral lesions using a brush-like device. The collected cells are then analyzed for abnormal changes indicative of malignancy [26].
- **Fluorescence Visualization (VELscope®):** VELscope is a fluorescence-based imaging device that emits blue light to enhance the visualization of oral mucosal abnormalities, including potentially malignant lesions, by detecting changes in tissue fluorescence patterns [27].

Salivary Biomarker Analysis: Salivary biomarker analysis involves the detection and measurement of specific biomolecules in saliva, such as proteins or nucleic acids, which may serve as indicators of oral cancer or its precursors [28].

Support and rehabilitation of a cancer patient

Supportive care and rehabilitation are vital components of oral cancer management. This may include oral hygiene instruction, prosthetic rehabilitation with dental implants or removable prostheses, and speech therapy to improve articulation and swallowing function.

Psychosocial support groups and counseling services also offer valuable support to patients and their families as they navigate the challenges of oral cancer survivorship. The needs are diverse and include issues such as health system and information needs [29], communication needs [30], needs related to the management of side effects of treatment [31], physical and daily living needs [32], and concerns about employment and return to work [33]. A recent study of unmet needs in head and neck cancer patients found that 68% of patients experienced unmet needs following treatment, with a majority of these needs falling in the psychological domain [34]. Moreover, individuals who were divorced, reported higher anxiety, experienced reduced emotional quality of life, or were in poorer physical condition were at risk for greater unmet needs.

Role of a dentist

Dental professionals collaborate with oncologists, speech therapists, and other healthcare providers to develop comprehensive care plans tailored to individual patients' needs. Before initiating cancer treatment, it is essential for a dentist to address any existing infections, dental caries, and tissue injuries or trauma in the oral cavity. Following a comprehensive oral prophylaxis, fluoride varnish should be topically applied every three months to prevent radiation-induced dental caries. Teeth within the radiation field that are beyond salvage and deciduous teeth that are mobile in children should be extracted. For patients using removable prostheses, meticulous cleaning and proper adaptation to oral tissues are imperative. Orthodontic bands and brackets should be removed if highly stomatotoxic chemotherapy or radiation therapy is planned, or if these appliances will be within the radiation field. Patient education plays a critical role in minimizing oral complications [35].

Furthermore, it is crucial for the dentist to meticulously document the patient's and their relatives' tobacco use profile. Effective tobacco cessation counseling can be provided through group, individual, or family counseling sessions. Carbon monoxide monitoring should also be conducted. Pharmacotherapy may be considered for patients who struggle to quit using voluntary methods. Regular follow-up visits with brief counseling sessions are essential to provide ongoing encouragement. Displaying educational materials and offering rewards to individuals who successfully quit smoking can further motivate patients to remain smoke-free [36].

- **Precision Medicine:** Tailoring treatment plans based on the genetic makeup of the tumor to improve efficacy and reduce side effects.

- **Immunotherapy:** Utilizing the patient's immune system to target and destroy cancer cells, offering new avenues for treatment with potentially fewer side effects.
- **Minimally Invasive Surgery:** Advances in surgical techniques allow for smaller incisions, shorter recovery times, and improved outcomes for oral cancer patients.
- **Targeted Therapies:** Drugs that specifically target molecules involved in cancer growth and progression, leading to more effective treatments with fewer systemic side effects.
- **3D Printing:** Customized implants and prosthetics can be created using 3D printing technology, enhancing surgical outcomes and patient comfort. Telemedicine: Remote consultations and follow-ups can improve access to care for patients, especially those in rural or underserved areas.
- **Liquid Biopsies:** Non-invasive tests that analyze blood or saliva for circulating tumor cells or DNA, aiding in early detection and monitoring of cancer progression.
- **Nanotechnology:** Nanoparticles can be used for targeted drug delivery or imaging of tumors, improving treatment efficacy and reducing damage to healthy tissues.
- **Robotic Surgery:** Robotic-assisted procedures offer enhanced precision and dexterity, particularly useful in delicate oral surgeries.
- **Multidisciplinary Care Teams:** Collaboration between oral surgeons, oncologists, radiologists, and other specialists ensures comprehensive and personalized care for cancer patients, leading to better outcomes.
- **Patient Education and Screening Programs:** Increased awareness about oral cancer risk factors, such as tobacco and alcohol use, as well as the importance of regular oral screenings, helps in early detection and prevention. Oral surgeons play a key role in educating patients about the signs and symptoms of oral cancer and encouraging participation in screening programs [37,38].
- **Reconstructive Surgery:** Advances in reconstructive surgery techniques, including microvascular free tissue transfer and tissue engineering, allow for restoration of form and function following tumor resection. Reconstruction plays a crucial role in improving quality of life for oral cancer survivors [37].

Reconstructive surgery plays a crucial role in the management of oral cancer patients, aiming to restore both form and function following tumor resection. Here's a detailed overview of reconstructive surgery in the context of oral cancer

- **Timing:** Reconstructive surgery may be performed immediately following tumor removal (primary reconstruction) or delayed until after completion of other treatments such as radiation therapy or chemotherapy (secondary reconstruction). The timing depends on various factors including the extent of the tumor, the need for adjuvant therapies, and the patient's overall health status.

Surgical Techniques

- **Local Flaps:** In cases where the defect is small and adjacent tissue is healthy, local tissue flaps may be used to reconstruct the surgical site. These flaps are comprised of skin, muscle, or a combination of both and are rotated or transposed to cover the defect [35].
- **Regional Flaps:** In more extensive defects, regional flaps sourced from adjacent areas with similar tissue characteristics may be utilized. Examples include pedicled flaps such as the deltopectoral flap or the pectoralis major myocutaneous flap [35].
- **Microvascular Free Tissue Transfer:** For large defects or when adequate local tissue is not available, microvascular free tissue transfer is often employed. This involves harvesting tissue from distant donor sites such as the forearm (radial forearm flap), thigh (anterolateral thigh flap), or abdomen (deep inferior epigastric perforator flap), and transferring it to the defect site along with its blood supply, usually through microsurgical techniques [37].
- **Bone Reconstruction:** In cases involving bony defects, bone grafts or microvascular techniques such as vascularized bone flaps may be utilized to restore skeletal integrity. Common donor sites for vascularized bone flaps include the fibula, scapula, and iliac crest [37].
- **Multidisciplinary Collaboration:** Reconstructive surgery for oral cancer often requires collaboration with other specialties such as plastic surgery, otolaryngology, maxillofacial surgery, and oncology. A multidisciplinary team approach ensures comprehensive evaluation and treatment planning tailored to each patient's unique needs [38].
- **Functional Restoration:** In addition to aesthetic considerations, reconstructive surgery aims to restore functional aspects such as speech, swallowing, mastication, and oral competence. Techniques such as dynamic muscle transfers, nerve grafting, and prosthetic rehabilitation may be employed to optimize functional outcomes [39].
- **Complications and Follow-up:** Reconstructive surgery carries inherent risks including wound healing complications, flap failure, infection, and functional impairment. Close post-operative monitoring and rehabilitation are essential to identify and address any complications promptly. Long-term follow-up is necessary to assess functional outcomes, monitor for disease recurrence, and provide supportive care [39].
- **Advancements and Future Directions:** Ongoing research in tissue engineering, regenerative medicine, and 3D printing holds promise for further advancements in reconstructive surgery for oral cancer. These technologies may offer innovative solutions for tissue regeneration and customized implants, enhancing both functional and aesthetic outcomes [36,40].

Artificial intelligence (ai) and machine learning

- Computer-Aided Diagnosis:** AI algorithms trained on large datasets of imaging and clinical data can aid in early detection and accurate diagnosis of oral cancer. Automated analysis of medical images and histopathological specimens may improve efficiency and accuracy in disease detection and classification [41].
- Treatment Planning and Prediction:** Machine learning models can assist clinicians in predicting treatment outcomes, optimizing treatment plans, and identifying patients at higher risk of disease recurrence or treatment-related complications [42].

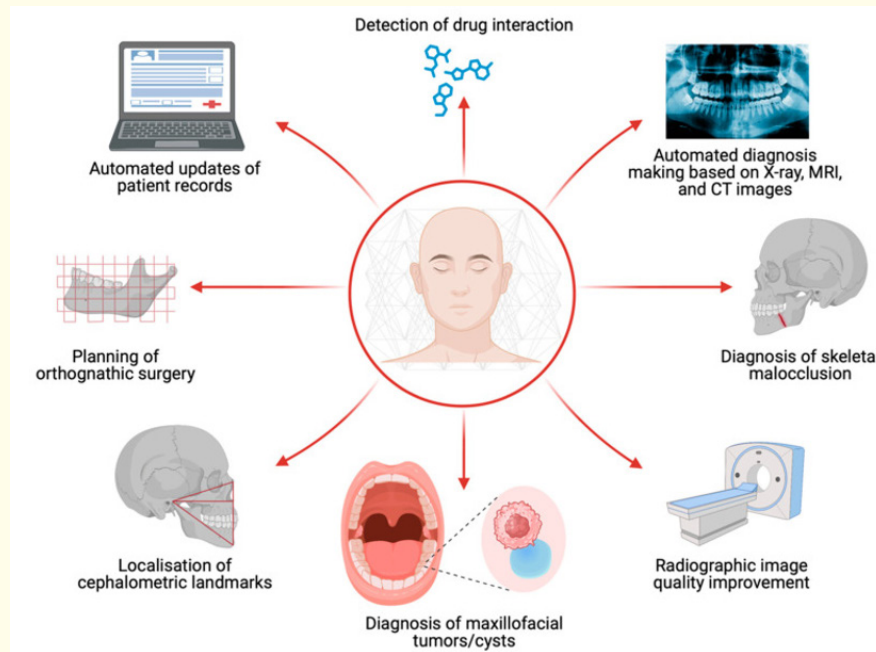


Figure 1

Artificial intelligence (AI) can be used for a wide array of clinical scenarios in oral and maxillofacial surgery Figure 1. For instance, AI can facilitate the diagnosis of maxillofacial tumorous lesions and enhance the localization precision of cephalometric landmarks [42].

Conclusion

In conclusion, oral cancer represents a significant global health challenge characterized by high mortality and morbidity rates, as well as poor prognosis and low survival rates. The diagnosis and treatment of oral cancer bring about numerous health-related complications and often lead to psychological challenges for affected individuals. Dentists play a vital role throughout the entire continuum of oral cancer care, from early detection and prevention to ongoing management and supportive care. Their expertise and vigilance are essential in improving outcomes and enhancing the overall well-being of patients.

This review highlights the profound psychosocial impact experienced by oral cancer patients and emphasizes the crucial role of dentists in addressing these challenges. By acknowledging and addressing the psychological aspects of oral cancer, healthcare professionals can better support patients through their cancer journey. Additionally, the review outlines various techniques for managing oral cancer postoperatively, with a focus on optimizing patient re-

covery and enhancing quality of life.

Moving forward, continued research and collaboration among healthcare professionals are essential to further advance our understanding of oral cancer and improve patient care. By integrating comprehensive care approaches that encompass both physical and psychosocial aspects, we can strive towards better outcomes

Bibliography

- Kamatchinathan P, *et al.* "Psychological Analysis of Oral Cancer Patients during Pre-operative Period in South Indian Population: A Prospective, Quantitative, Multicentre Study". *Journal of Clinical and Diagnostic Research* 10.10 (2016): ZC72-ZC74.
- Kumar A, *et al.* "Arsenic exposure in Indo Gangetic plains of Bihar causing increased cancer risk". *Scientific Reports* 11 (2021): 2376.
- Larouche S and Edgar L. "Concept analysis of social support". *Cancer Nursing* 27.1 (2004): 18-29.
- Holland JC. "History of psycho-oncology: overcoming attitudinal and conceptual barriers". *Psychosomatic Medicine* 64.2 (2002): 206-221.

5. Hassanein KA, et al. "Psychological outcome of patients following treatment of oral cancer and its relation with functional status and coping mechanisms". *Journal of Cranio-Maxillofacial Surgery* 33 (2017): 404-409.
6. Verdonck-de Leeuw IM, et al. "Distress in spouses and patients after treatment for head and neck cancer". *Laryngoscope* 117 (2017): 238-241.
7. Chen ML and Chang HK. "Physical symptom profiles of depressed and nondepressed patients with cancer". *Palliative Medicine* 18 (2017): 712-718.
8. Llewellyn CD, et al. "Are psycho-social and behavioural factors related to health related-quality of life in patients with head and neck cancer? A systematic review". *Oral Oncology* 41 (2017): 440-454.
9. Yuen HK, et al. "Negative psychosocial consequence of self-restricted driving among cancer survivors in the head and neck region". *Clinical Otolaryngology* 34 (2017): 395-396.
10. Vardy J and Tannock I. "Cognitive function after chemotherapy in adults with solid tumours". *Critical Reviews in Oncology/Hematology* 63.3 (2017): 183-202.
11. Katz MR, et al. "Reliability and Validity of an Observer-Rated Disfigurement Scale for Head and Neck Cancer Patients". *Head Neck* 22 (2000): 132-141.
12. Wang TJ, et al. "Influences of Facial Disfigurement and Social Support for Psychosocial Adjustment among Patients with Oral Cancer in Taiwan: A Cross Sectional Study". *BMJ Open* 8 (2018): e023670.
13. Rifkin WJ, et al. "Facial Disfigurement and Identity: A Review of the Literature and Implications for Facial Transplantation". *AMA Journal of Ethics* 20 (2018): 309-323.
14. Khawaja SN, et al. "Prevalence of Pain in Oral Cancer: A retrospective study". *Oral Diseases* 27 (2021): 1806-1812.
15. Ou M, et al. "Perioperative Symptom Burden and Its Influencing Factors in Patients with Oral Cancer: A Longitudinal Study". *Asia-Pacific Journal of Oncology Nursing* 9 (2022): 100073.
16. Jagannathan A and Juvva S. "Emotions and Coping of Patients with Head and Neck Cancers after Diagnosis: A Qualitative Content Analysis". *Journal of Postgraduate Medicine* 62 (2012): 143.
17. G Abbey, et al. "A meta-analysis of prevalence rates and moderating factors for cancer-related post-traumatic stress disorder". *Psycho-oncology* 24 (2015): 371-381.
18. S Yamaguchi, et al. "Psychological impact on patients with oral cancer before undergoing resection and free flap reconstruction surgery". *Oral Oncology Reports* 3-4 (2022): 100004.
19. Ranjan P. "How can Doctors Improve their Communication Skills?" *Journal of Clinical and Diagnostic Research* 9 (2006): JE01.
20. Surbone A. "Telling the truth to patients with cancer: What is the truth?" *Lancet Oncology* 7 (2006): 944-950.
21. Alves CGB, et al. "Strategies for communicating oral and oropharyngeal cancer diagnosis: Why talk about it?" *Oral Surgery, Oral Medicine, Oral Pathology and Oral Radiology* 129 (2000): 347-356.
22. Baile WF, et al. "SPIKES-A Six-Step Protocol for Delivering Bad News: Application to the Patient with Cancer". *Oncologist* 5 (2000): 302-311.
23. J Bagan, et al. "Oral Oncology 46 (2010): 414-417.
24. Yang EC, et al. "Noninvasive diagnostic adjuncts for the evaluation of potentially premalignant oral epithelial lesions: current limitations and future directions". *Oral Surgery, Oral Medicine, Oral Pathology and Oral Radiology* 125 (2018): 670-681.
25. Warnakulasuriya S. "Global epidemiology of oral and oropharyngeal cancer". *Oral Oncology* 45.4-5 (2009): 309-316.
26. Sciubba JJ. "Improving detection of precancerous and cancerous oral lesions". *Computerized Medical Imaging and Graphics* 25.5 (2001): 367-373.
27. Poh CF, et al. "Fluorescence visualization detection of field alterations in tumor margins of oral cancer patients". *Clinical Cancer Research* 12.22 (2006): 6716-6722.
28. Cheng YSL, et al. "Advanced salivary diagnostics for oral cancer detection". *Journal of the Formosan Medical Association* 113.7 (2014): 454-459.
29. Chen SC, et al. "Support needs of patients with oral cancer and burden to their family caregivers". *Cancer Nursing* 32.6 (2009): 473-481.
30. Swore Fletcher B, et al. "A blessing and a curse: head and neck cancer survivors' experiences". *Cancer Nursing* 35.2 (2012): 126-132.
31. Moore KA, et al. "I have quality of life...but...": exploring support needs important to quality of life in head and neck cancer". *European Journal of Oncology Nursing* 18.2 (2014): 192-200.
32. Chen S-C, et al. "Distress and care needs in newly diagnosed oral cavity cancer patients receiving surgery". *Oral Oncology* 45.9 (2009): 815-820.
33. Llewellyn CD, et al. "Assessing the psychological predictors of benefit finding in patients with head and neck cancer". *Psycho-Oncology* 22.1 (2013): 97-105.

34. Campbell HS., *et al.* "Psychometric properties of cancer survivors' unmet needs survey". *Support Care Cancer* 19.2 (2011): 221-230.
35. U.S. Department of Health and Human Services National Institutes of Health National Institute of Dental and Craniofacial Research. Oral Complications of Cancer Treatment: What the Dental Team Can Do. Rockville, MD: U.S. Department of Health and Human Services National Institutes of Health National Institute of Dental and Craniofacial Research (2000).
36. National Guidelines for Tobacco Cessation. Ministry of Health and Family Welfare, Govt of India.
37. Vermorcken JB., *et al.* "Role of molecular markers in DPFS (disease-free survival) and OS (overall survival) of locally advanced oral cancer treated with postoperative radiotherapy (PORT) in the phase III randomized TROG 05.01 trial". *Annals of Oncology* 32.5 (2021): 629-638.
38. Solares CA., *et al.* "Transoral robotic surgery (TORS) for the treatment of head and neck cancer". *Cancer Journal* 19.3 (2013): 267-276.
39. Giesel FL., *et al.* "68Ga-FAPI PET/CT: biodistribution and preliminary dosimetry estimate of 2 DOTA-containing FAP-targeting agents in patients with various cancers". *Journal of Nuclear Medicine* 60.3 (2019): 386-392.
40. Datta P., *et al.* "Bioprinting for vascular and vascularized tissue biofabrication". *Acta Biomaterialia* 51 (2017): 1-20.
41. Esteva A., *et al.* "Dermatologist-level classification of skin cancer with deep neural networks". *Nature* 542.7639 (2017): 115-118.
42. Miragall MF., *et al.* "Face the Future-Artificial Intelligence in Oral and Maxillofacial Surgery". *Journal of Clinical Medicine* 12.21 (2023): 6843.